

Evaluation of Echocardiographic Parameters in Patients with Rhythm Disorders Associated with Chronic Hepatic Diseases

VERONICA CALBOREAN¹, ION UDRISTOIU^{2*}, ANDREEA DENISA DOCEA³, MIHAI CRISTIAN HODOROG⁴,
SORIN NICOLAE DINESCU⁵, OANA CRICIOTOIU⁶, DIANA STANCA⁶, ADRIAN MITA⁷, DRAGOS VIRGIL DAVITOIU⁸,
VLAD DUMITRU BALEANU⁹, FLORIN MARIUS ROMANESCU¹⁰, MARIUS BICA¹¹, CECIL SORIN MIREA¹¹,
VENERA CRISTINA DINESCU¹²

¹University of Medicine and Pharmacy of Craiova, Cardiology Department, 2 Petru Rares Str., 200349, Craiova, Romania

²University of Medicine and Pharmacy of Craiova, Psychiatry Department, Neuropsychiatry Hospital of Craiova, 24 Alea Potelu Str., 200473, Craiova, Romania

³University of Medicine and Pharmacy of Craiova, Gynecology Department, 2 Petru Rares Str., 200349, Craiova, Romania

⁴University of Medicine and Pharmacy of Craiova, Department of Urology, 2 Petru Rares Str., 200349, Craiova, Romania

⁵University of Medicine and Pharmacy of Craiova, Epidemiology and Primary Health Care Department, 2 Petru Rares Str., 200349, Craiova, Romania

⁶University of Medicine and Pharmacy of Craiova, Neurology Department, Neuropsychiatry Hospital of Craiova, 99 Calea Bucuresti Str., 200473, Craiova, Romania

⁷University of Medicine and Pharmacy of Craiova, Internal Medicine Department, Filantropia Hospital of Craiova, 1 Filantropiei Str., 200143, Craiova, Romania

⁸University of Medicine and Pharmacy of Bucharest, Surgery Department, Clinical Emergency Hospital Sf. Pantelimon Bucharest, 340-343 Pantelimon Road, 021659, Bucharest, Romania

⁹University of Medicine and Pharmacy of Craiova, Surgery Department, Clinical Emergency Hospital Sf. Pantelimon Bucharest, 340-343 Pantelimon Road, 021659, Bucharest, Romania

¹⁰University of Medicine and Pharmacy of Craiova, Department of Physiology, 2 Petru Rares Str., 200349, Craiova, Romania

¹¹University of Medicine and Pharmacy of Craiova, Surgery Department, 2 Petru Rares Str., 200349, Craiova, Romania

¹²University of Medicine and Pharmacy of Craiova, Health Promotion and Occupational Medicine Department, 2 Petru Rares Str., 200349, Craiova, Romania

Due to the increased frequency of cardiovascular diseases in the evolution of chronic liver disease, we proposed to assess echocardiographic changes in patients with rhythm disorders associated with chronic liver disease. To analyze the degree of cardiac damage, each patient was subjected to a complete cardiovascular examination.

Keywords: hepatic disease, echocardiographic examination, cardiac affection

Rhythm disorders refer to the abnormality or disturbance of the normal myocardial activation sequence [1-6]. This indicates structural cardiac disease and may be the cause of significant cardiovascular complications and sudden cardiac death [5-11].

Regardless of its etiology spectrum, the hepatic disease leads to changes in the structure and functions of the heart, mostly with latent, infra-clinical progression, often recognized by clinicians with difficulty [12-15].

Cardiovascular diseases are one of the leading causes of death in the world [16-17]. Rhythm disorders are associated with increased morbidity and mortality [18-19]. The association between chronic hepatic disease and rhythm disorders causes additional comorbidities [20-24]. Early recognition of the underlying causes of cardiovascular disease, of the clinical and para-clinical test and the modifiable risk factors, determine its rate of progression and focus on preventive treatment and possible complications of the chronic hepatic disease [21-24].

The diversity of the etiological factors of chronic liver disease involves investigating each aspect of the arrhythmogenic substrate and assessing its triggering and aggravating factors in order to obtain a diagnosis of high probability and practical utility.

Experimental part

The aim of the study

In our study, 126 patients were diagnosed based on the clinical and para-clinical tests with chronic hepatic disease

and 120 patients without chronic liver disease, representing the control group.

The study was conducted over a period of 14 months, from 1.10.2016 to 1.01.2018

The purpose of our study was to assess the echocardiographic parameters in patients with rhythm disorders associated with chronic hepatic disease.

We have correlated different signs of cardiac damage, those characteristic of systolic and diastolic dysfunction with the etiology of chronic liver disease.

To analyze the degree of cardiac damage, each subject in our research (study lot plus control lot) was subjected to a complete cardiovascular examination:

- Anamnesis and clinical examination of the cardiovascular system, with evaluation of positive signs and symptoms, specific to heart disease

- Echocardiography for the evaluation of cardiac changes. We studied left ventricular function, left ventricular diameters both in systole and diastole, left ventricular posterior wall, right ventricle, right atrium, left atrium, and interventricular septum.

Results and discussions

The echocardiographic examination was influenced by a number of factors. These include obesity, pulmonary emphysema, altered somatic status, psychomotor restlessness and agitation so frequently encountered in patients with cardiac impairment [25].

We have noticed a series of correlations between various morphological and functional cardiac changes and comorbid hepatic pathology. These data are consistent with the literature that states that both diastolic and systolic function are altered in liver cirrhosis [18]. These changes in ventricular function are accentuated under stress conditions [3,23-24]. Some studies show that diastolic dysfunction is present in all patients diagnosed with chronic liver disease[26]. Although these morphological changes are not in a relationship of direct proportionality with diastolic dysfunction, we consider that echocardiography plays a fundamental role in the early detection of systolic and diastolic dysfunctions [26].

We have granted great importance to the analysis of the left atrium diameter since changes to it may bring alarm signals for the installation of severe heart disease.

It is known that the diameter of the left atrium is a marker of diastolic dysfunction. It is also known that many markers of diastolic failure normalize with the adjustment of the filling pressure, while the left atrium diameter remains a long time increased [27-29] (fig. 1).

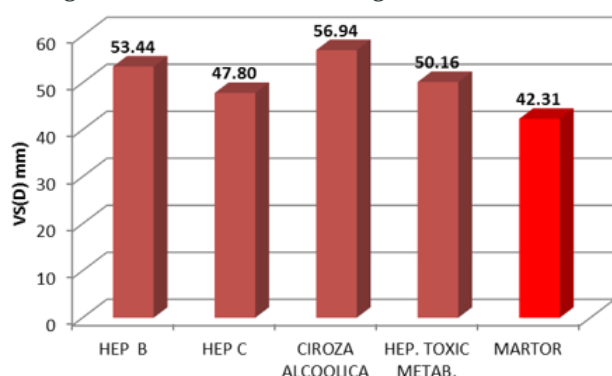


Fig. 1. Echocardiographic analysis of left ventricle in diastole. Correlations with the etiology of liver disease

The mean VS (D) diameter in patients with chronic hepatic disease, depending on etiology, was 53.44 mm for patients diagnosed with chronic viral hepatitis B, 47.8 mm for subjects with chronic viral hepatitis C, 56.94 for patients diagnosed with alcoholic cirrhosis and 50.16 mm for patients with toxic-metabolic hepatitis. The mean VS (D) for the control group was 42.31 mm.

Comparing the mean value of VS (D) according to liver disease etiology with the mean value of the control group, we noticed a significant difference using the Student t test (Student t test <0.0001).

This markedly significant difference was recorded to all of the patients with liver disease from our study group (fig. 2).

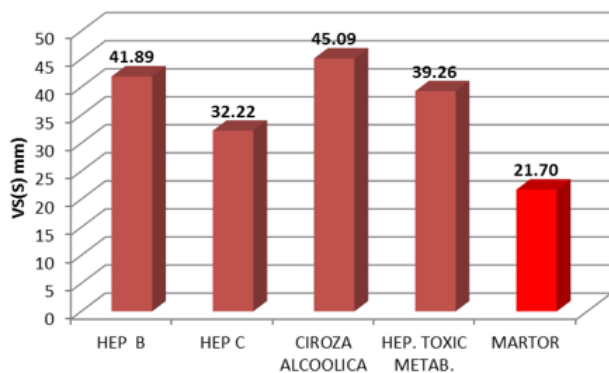


Fig. 2. Echocardiographic analysis of left ventricle in systole. Correlations with the etiology of liver disease.

Analyzing the mean as a statistical indicator, we obtained the following results: 41.89 - mean for chronic viral hepatitis B, 32.22 for chronic viral hepatitis C, 45.09 for patients with alcoholic cirrhosis and 39.26 for patients with metabolic toxic hepatitis .

It should be noted that the mean of the control group registered the value of 21.7 mm, as it can be seen a much lower value than those recorded in the patients from the study group.

The significant difference from the control group was high. This was also confirmed by the results of the Student t test (p <0.0001) (fig. 3).

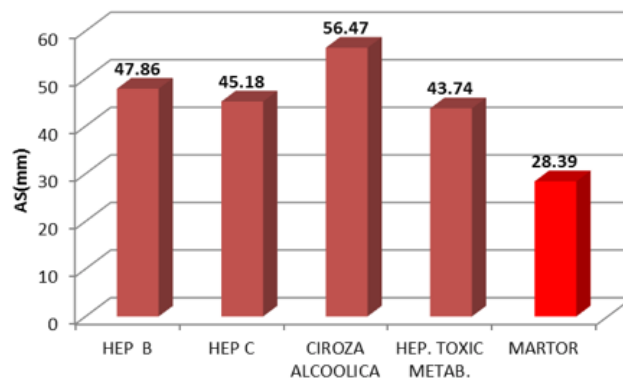


Fig. 3. Echocardiographic analysis of left atrium (AS). Correlations with the etiology of liver disease

We obtained the following mean values of left atrium: 47.86 mm for patients with chronic viral hepatitis B, 45.18 mm for patients with chronic viral hepatitis C, 56.47 mm for patients with alcoholic cirrhosis and 43.74 mm for the diagnosed subjects with metabolic toxic hepatitis.

The analysis with the control group shows significant differences both by comparing the recorded value from the control group (28.39mm) vs the mean value of the study group (48.83mm) and through the results of the Student test (P <0.0001) (fig. 4).

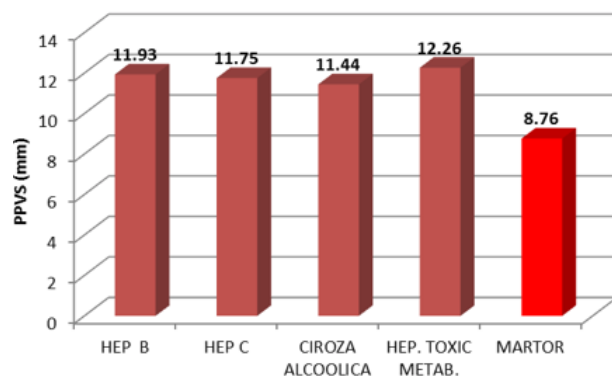


Fig. 4. Echocardiographic analysis of left ventricular posterior wall (PPVS). Correlations with the etiology of liver disease

The mean value of the left ventricular posterior wall relative to the entire nostologic palette of our research was 11.80 mm. It was divided into etiologies as follows: 11.93 mm - chronic viral hepatitis B, 11.75 mm - chronic viral hepatitis C, 11.44 mm - alcoholic cirrhosis and 12.26 mm - metabolic toxic hepatitis.

The left ventricular posterior wall mean for the control group was 8.76 mm. This clear difference between the study group and the control group is also reinforced by the statistical analysis where the p value of the Student test is less than 0.0001 (fig. 5).

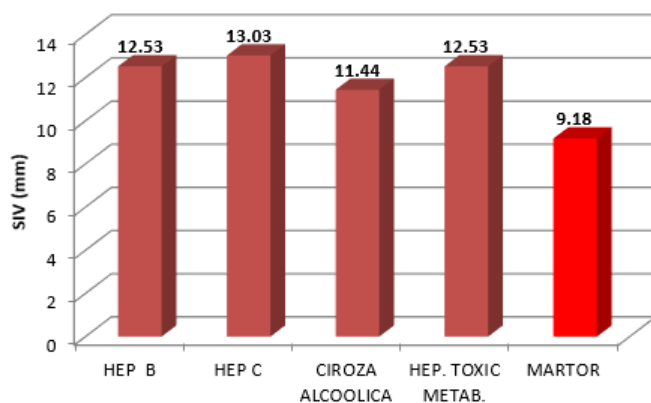


Fig. 5. Echocardiographic analysis of interventricular septum (SIV). Correlations with the etiology of liver disease

Interventricular septum mean values had the following data: 12.53 mm for chronic viral hepatitis B, 13.03 mm for chronic viral hepatitis C, 11.44 mm for alcoholic cirrhosis, and 12.53 for metabolic toxic hepatitis.

The total diameter mean value of the interventricular septum for the study group is 12.37 mm, while the total mean of the interventricular septum for the control group is 9.18 mm.

This significant difference is also statistically confirmed by the Student t test ($p < 0.0001$) (fig. 6).

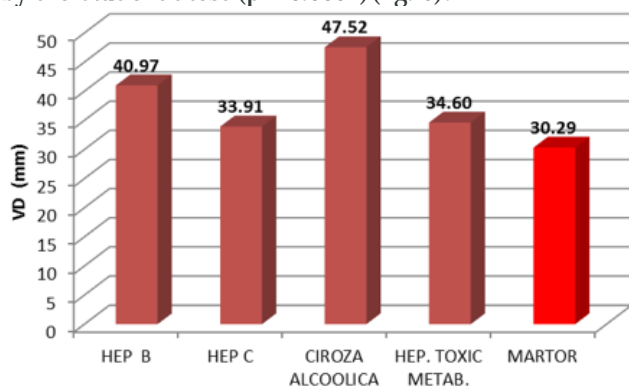


Fig. 6. Echocardiographic analysis of the right ventricle (VD). Correlations with the etiology of liver disease

The mean VD diameter for patients with chronic viral hepatitis B was 40.97 mm, for those with chronic viral hepatitis C 33.91 mm, 47.52 mm for patients with alcoholic cirrhosis and 34.60 mm for those with metabolic toxic hepatitis. We note, therefore, an average of 39.97 mm for patients from the study group versus an average of 30.29 mm for patients from the control group.

The Student t test shows significant differences between the ventricular diameter value for the study lot / control lot on the following pathologies: chronic viral hepatitis B, chronic viral hepatitis C and alcoholic cirrhosis. Regarding metabolic toxic hepatitis, there were no significant differences from the control group ($p = 0.119$) (fig. 7).

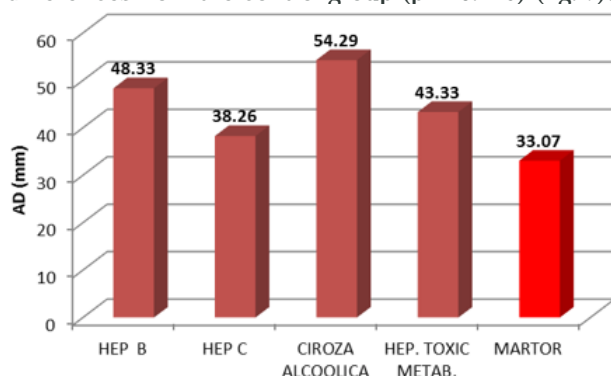


Fig. 7. Echocardiographic analysis of right atrium (AD). Correlations with the etiology of liver disease

The mean of the studied lot showed a total value of the right atrium of 46.54 mm.

For patients with chronic viral hepatitis B was 48.33 mm, for those diagnosed with chronic viral hepatitis C the value was 38.26 mm, 54.29 mm for patients with alcoholic cirrhosis and 43.33 mm for those with metabolic toxic hepatitis.

The mean for the control lot regarding right atrium diameter was 33.07 mm.

The Student t test recorded significant differences (Student test < 0.0001) for all the hepatic etiologies from the subjects in our group (viral, alcoholic and metabolic toxic etiology) (fig. 8).

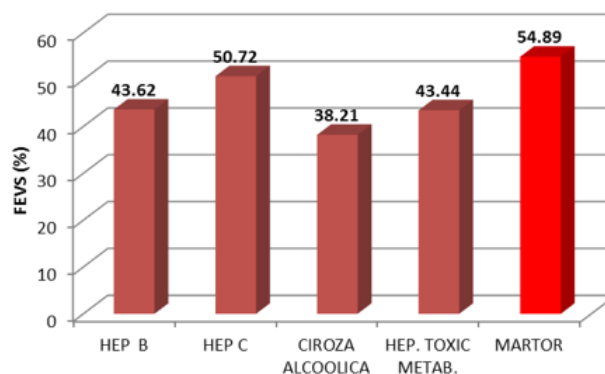


Fig. 8. Echocardiographic analysis of left ventricular ejection fraction (FEVS). Correlations with the etiology of liver disease

The mean of left ventricular ejection fraction in our patients from the study group it was different according to the etiology of hepatic disease. In patients with alcoholic cirrhosis it was 38.21%, in those with metabolic toxic hepatitis 43.44%, in those with chronic viral hepatitis B 43.62% and the highest mean was recorded in patients with chronic viral hepatitis C (50.72%).

The total average of left ventricular ejection fraction was 43.97%, much lower than the control group (54.89%).

This significant difference is confirmed by the Student t test ($p < 0.0001$) (fig. 9).

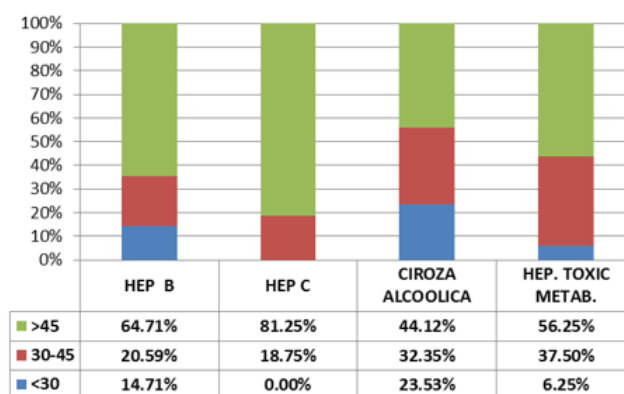


Fig. 9

We divided the group into three categories according to the left ventricular ejection fraction, namely: the first category included patients with left ventricular ejection fraction of less than 30%, the second category had targeted subjects with FEVS between 30 and 45% and the third category included patients with a left ventricular ejection fraction greater than 45%.

As can be seen from the graph above, most patients with FEVS below 30% were those diagnosed with alcoholic cirrhosis. On the second place were patients diagnosed with chronic viral hepatitis B.

A percentage of 6.25% of patients with metabolic toxic hepatitis had FEVS $< 30\%$. None of the patients diagnosed

with chronic viral hepatitis C had a left ventricular ejection fraction less than 30%.

Analyzing the 30-45% interval of left ventricular ejection fraction we can see that the highest percentage is recorded in the diagnostic group with metabolic toxic hepatitis (37.50%). On the second place are subjects diagnosed with alcoholic cirrhosis, where over 32% of the patients suffering from this pathology recorded FEVS values between 30-45%. With FEVS between 30-45% were fewer subjects diagnosed with chronic viral hepatic disease (20.59% of patients with chronic viral hepatitis B and 18.75% patients with chronic viral hepatitis C).

The best results of the left ventricular ejection fraction were recorded in patients diagnosed with chronic viral hepatitis C. Over 81% of these patients had values of FEVS above 45%.

Conclusions

Echocardiography is a simple and non-invasive method, but extremely useful for preventing severe heart disease.

All of our correlations were reinforced by statistically significant differences between the study group and the control group, confirmed by the mean study, the standard deviation and the Student t test.

References

- 1.FORTOFOIU, M., FORTOFOIU, M.C., COMANESCU, V., DOBRINESCU, A.C., PADUREANU, V., VERE, C.C., STREBA, C.T., CIUREA, P.L. *Rom J Morphol Embryol* 2015, vol 56, p. 1461-1465.
- 2.CALBOREAN, V., CIOBANU, D., MIREA, S.C., GALCEAVA, O., GHEORMAN, V., PADUREANU, V., FORTOFOIU, C.M., FORTOFOIU, M., MITA, A., DINESCU, S.N., MISCOCI, S.A., DINESCU, V.C., *Rev. Chim. (Bucharest)*, **69**, nr. 9, 2018, p.2744-2748.
- 3.GHEORMAN, V., MILITARU, F., CALBOREAN, V., GHEORMAN, L.M., CHIRITA, A.L., MITA, A., GALCEAVA, O., GHEORMAN, V., STANCA, D., UDRISTOIU, I., *Rev. Chim. (Bucharest)*, **69**, no. 4, 2018, p.881-885.
- 4.GHEORMAN, V., CHIRITA, A.L., DUMITRESCU, E.M., ROGOVEANU, I., ISTRATOIE, O., GHEORMAN, V., PANU, R.C. *Rom J Morphol Embryol*, 2016, 57(1): 45-50.
- 5.CALBOREAN, V., GHEORMAN, V., DINESCU, S.N., STANCA, D., GALCEAVA, O., FORTOFOIU, M., MITA, A., MIHAILOVICI, A.R., MISCOCI, S.A., BALEANU, V.D., DINESCU, V.C., *Rev. Chim. (Bucharest)*, **69**, no. 11, 2018, p.4237- 4240
- 6.PETRESCU, F., PETRESCU, O.I., TAISESCU, C.I., COMANESCU, M.V., FORTOFOIU, M.C., PREDESCU, I.O., ROSU, A.F., GHEONEA, C., BICIUSCA, V. *Rom J Morphol Embryol* , 2015, vol 56, p. 439-444.
- 7.CALBOREAN, V., GHEORMAN, V., OCTAVIAN, I., MUSTAFA, R.E., COJOCARU, P.A., ALEXANDRU, D.O., GALCEAVA, O., MITA, A., MISCOCI, S.A., ALNAMAT, R., GHEONEA, D.I. *Rev. Chim. (Bucharest)*, **69**, no. 5, 2018, p.1134-1138.
- 8.MESINA, C., VASILE, I., VILCEA, I. D., PASALEGA, M., CALOTA, F., PARVANESCU, H., DUMITRESCU, T., MIREA, C., MOGOANTA, S. *Chirurgia*, nr. 3, Vol. 108, 2013, p. 400-406.
- 9.PASALEGA, M., MIREA, C., VILCEA, I. D., VASILE, I., PLESEA, E., CALOTA, F., MESINA, C., PARVANESCU, H., BALUTA, M. *Romanian Journal of Morphology and Embryology*, nr. S1, Vol. 52, 2011, p. 503-508.
10. MESINA, C., VASILE, I., VILCEA I. D., PASALEGA, M., PARVANESCU, H., CALOTA, F., GEORGESCU, C.V., GHILUSI, M., DUMITRESCU, T., MIREA, C., MOGOANTA, S., MORARU, E. *Chirurgia*, nr. 2, Vol. 105, 2010, p. 257-266.

- 11.CIOBANU, D., MESINA, C., STREBA, L., GRUIA, C.L., DITESCU D., SARLA C. G., ENESCU, A., PETRESCU, F. *Rom J Morphol Embryol* 2014, vol 55 (3 Suppl).
- 12.CALBOREAN, V., MISCOCI, S. A., ISTRATOIE, O., GALCEAVA, O., ALEXANDRU, D.O., GUTA, M.M., GHEORMAN, V., PADUREANU, V., FORTOFOIU, C.M., DIJMARESCU, A.L., GHEONEA, D.I. *Rev Chim (Bucharest)*, **69**, no. 6, 2018, p. 1527-1532.
- 13.PUIU, I., ALBU, C.V., TARTEA, E.A., CALBOREAN, V., GHEORMAN, V., DINESCU, S.N., VASILE, R.C., DINESCU, V.C., BICA, E.C., ROMANESCU, F.M., TUDORASCU, D.R. *Rev Chim (Bucharest)*, **69**, no. 10, 2018, p. 2744-2748.
- 14.ENE, C.G., ROSU, A., GHEORMAN, V., CALBOREAN, V., TENEA COJAN, T.S., ROGOVEANU, O.C., VLADU, M.I., RADU, L. *Rev Chim. (Bucharest)*, **69**, no. 7, 2018, p.1851-1854.
15. VLADU, I.M., RADU, L., GIRGAVU, S.R., TENEA COJAN, T.S., ENE, C.G., CALBOREAN, V., GHEORMAN, V., CLENCIU, D. *Rev. Chim. (Bucharest)*, **69**, no. 9, 2018, p.2479-2481.
- 16.CALBOREAN, V., GHEORMAN, V., AL NAMAT, R., CAZACU, I. M., VARJU, P., GEDE, N., STREBA, T.C., VERE, C.C., GHEONEA, D.I., GHEORMAN, V., LUNGULESCU, C., LUNGULESCU, C., V. *Rev. Chim. (Bucharest)*, **68**, no. 12, 2017, p.3010-3014
- 17.MIHAILOVICI, A.R., PADUREANU, V., ALBU, C.V. DINESCU, V.C., PIRLOG, M.C., DINESCU, S.N., MALIN, R.D., CALBOREAN, V., *Rev. Chim. (Bucharest)*, **69**, no. 8, 2018, p 2209-2212.
- 18.CORICI, O. A., TANASIE, C.A., ALEXANDRU, D.O., FLORESCU, C.M., COMANESCU, M.V., KAMAL, C., TENEA-COJAN, T.S., IANCAU, M., DINESCU, S.N. *Rom J Morphol Embryol*; 2018; 59(1):93-103.
- 19.BALEANU, V.D., CONSTANTIN, D.V., PASCAL, A., ALEXANDRU, D.O., BOBIC, S., SOCEA, B., MANDA, A.L., DAVITOIU, D.; DIJMARESCU, A.L., GEORGESCU, I., MIREA, C.S. *Rev Chim (Bucharest)*, **69**, no. 7, 2018, p 1740-1743.
- 20.NOVA, M.V., NICULESCU, M., MANOLEA, M.M., DIJMARESCU, A.L., ILIESCU, D.G., NOVA, M.B., ROTARU, L.T., STOENESCU, M.F., TABACU, M.C., TUDORACHE, S., BUSUIOC, C.J., GHEONEA, I.A. *Rom J Morphol Embryol* , 2018, vol 59, p. 715-720.
- 21.STOENESCU, V.E., NICULESCU, M., NOVA, L., MANOLEA, M.M., TOMESCU, P.I., DIJMARESCU, A.L., NOVA, M.B., TUDORACHE, S., ILIESCU, D.G. *Rom J Morphol Embryol* , 2017, vol 58, p. 791-800.
- 22.SIMINEL, M.A., GHEONEA, C., STANESCU, M.R., COMANESCU, A.C., DIJMARESCU, A.L., NEAMTU, S.D., COTOI, B.V., NEDELUTA, R.M., NICULESCU, E.C. *Rom J Morphol Embryol* , 2015, vol 56, p.301-308.
- 23.BUICU, G.E., GRECU, M.G., SALCUDEAN, A., GRECU, I.G., MARINESCU, C., NIRESTEAN, A., TURLIUC, S., HADAREANU, V., UDRISTOIU, I. *EUROPEAN PSYCHIATRY*, 41, 2017, p. S583-S584.
- 24.CHIMORGACHI, A., COSNTANTIN, M.D.G., UDRISTOIU, T., PIRLOG, M.C., UDRISTOIU, I. *JOURNAL OF NEURAL TRANSMISSION*, 114, issue 7, 2007, p. CXX-CXX.
- 25.NAGATA, Y., KADO, Y., ONOUE, T., et al. *Echo Research and Practice*. 2018; 5(1):27-39.
26. SAMPAIO, F., PIMENTA, J., BETTENCOURT, N., FONTES-CARVALHO, R., SILVA, A.P., VALENTE, J., BETTENCOURT, P., FRAGA, J., GAMA, V. *Liver Int.* 2013 Sep; 33(8):1158-65.
27. LI, X., YU, S., LI, L., HAN, D., DAI, S., & GAO, Y. (2014). *International Journal of Clinical and Experimental Medicine*, 7(12), p.5751-5757.
- 28.TRASCA, S.P., FLORESCU, C., DINESCU, V.C., PUIU, I., DINESCU, S.N., TUDORASCU, D.R., BICA, C., VASILE, R.C., ROMANESCU, F.M., BUNESCU, M.G., CIOATERA, N., GOANTA, E.V., *Rev. Chim. (Bucharest)*, 2018, **69**, no.12, p.3600-3604.
- 29.CALBOREAN, V., GHEORMAN, V., CONSTANTIN, C., ISTRATOIE, O. *Journal of Cardiovascular Emergencies*, 2018, 4, nr.2, p. 101-105

Manuscript received: 7.08.2018